

325

No. [Redacted]

Name _____

Order _____

Remarks _____

Retouched _____

Order Finished _____

Reorder _____

Reorder _____

5-9-45 Scan

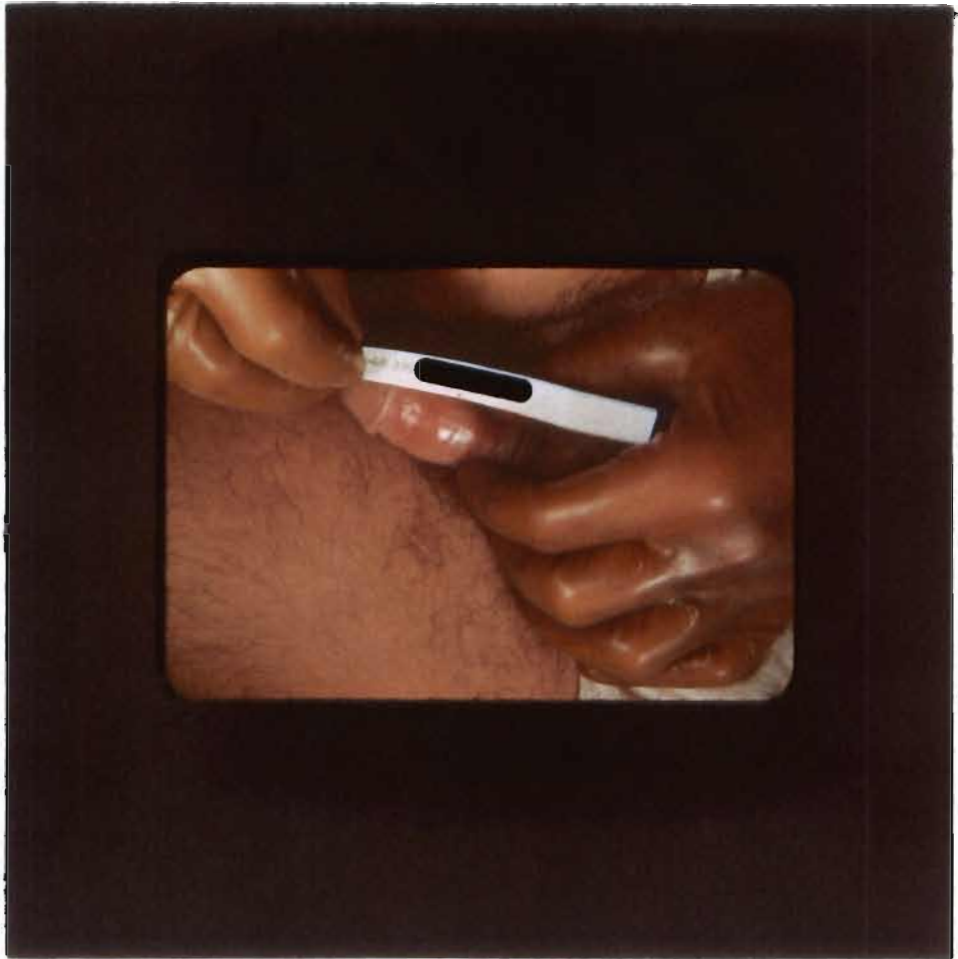6-24-45 46d

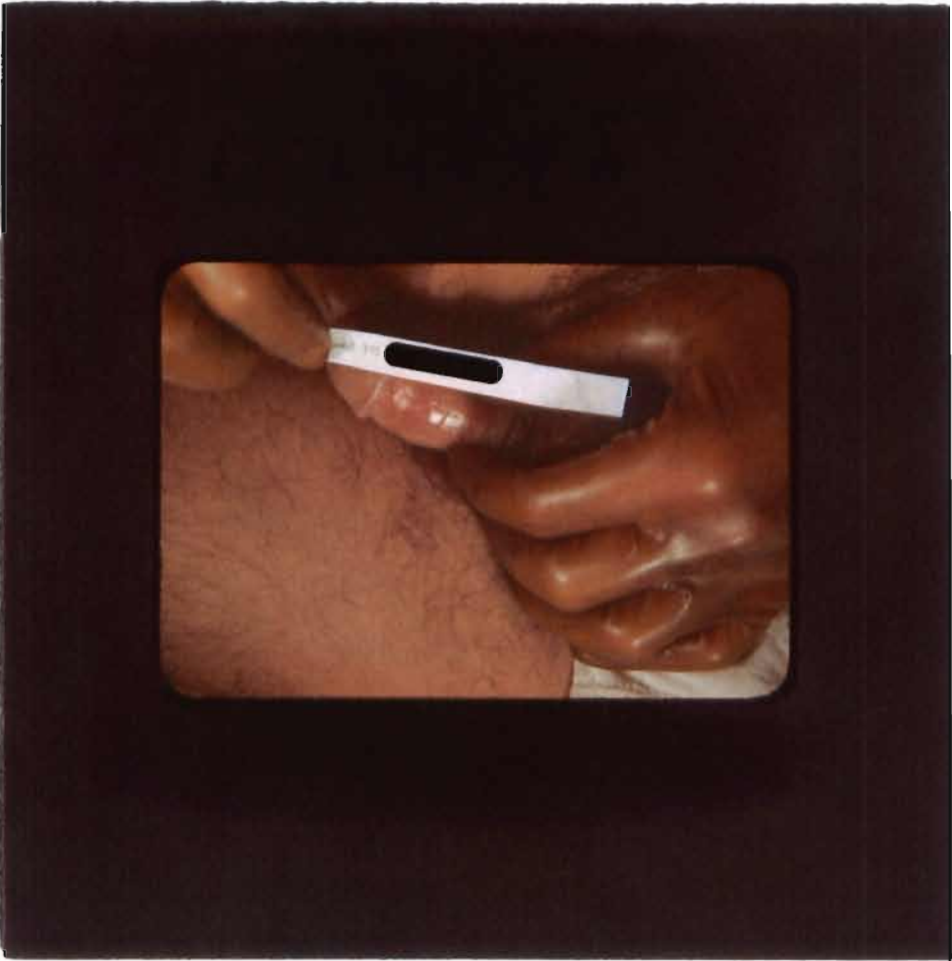2x2 mm
eroded, indicated
area.

325

E







327

No. [redacted]

Name _____

Order _____

Remarks _____

Retouched _____

Order Finished _____

Reorder _____

Reorder _____

[redacted]

5-9-48 Scan

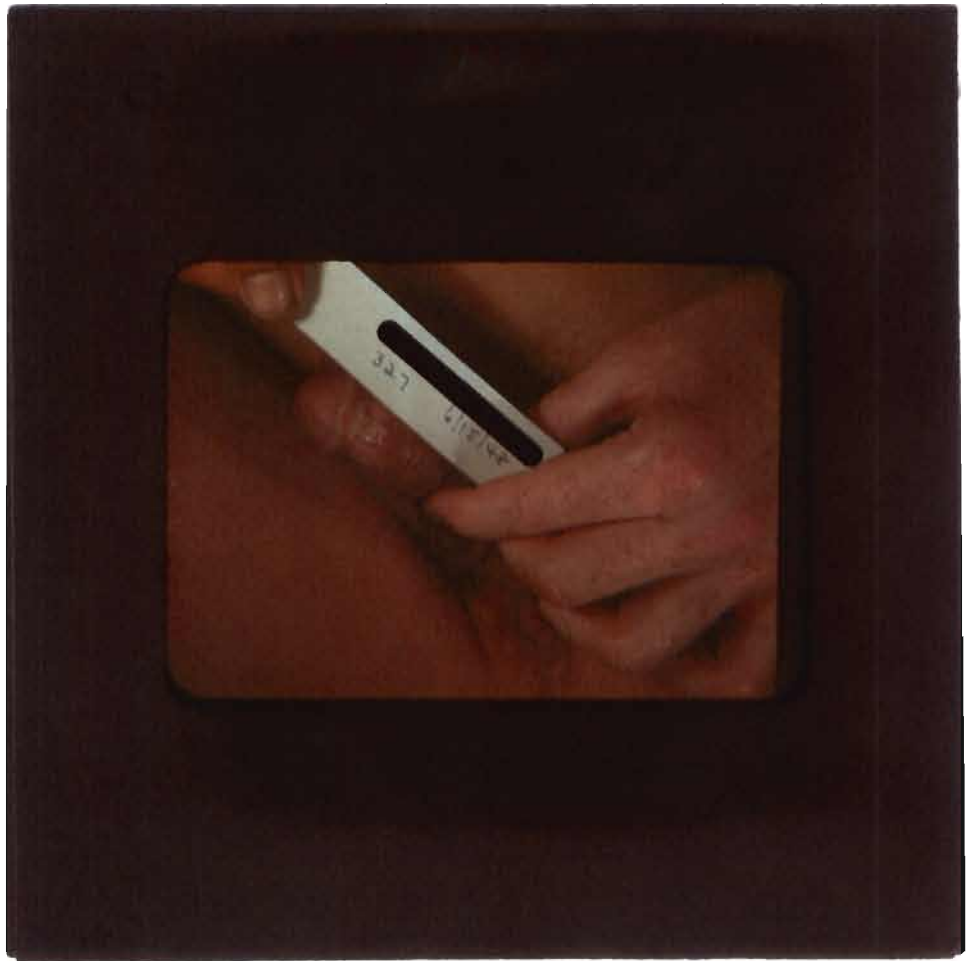6-15-37 2mm papule on cheek
of chin + erosion

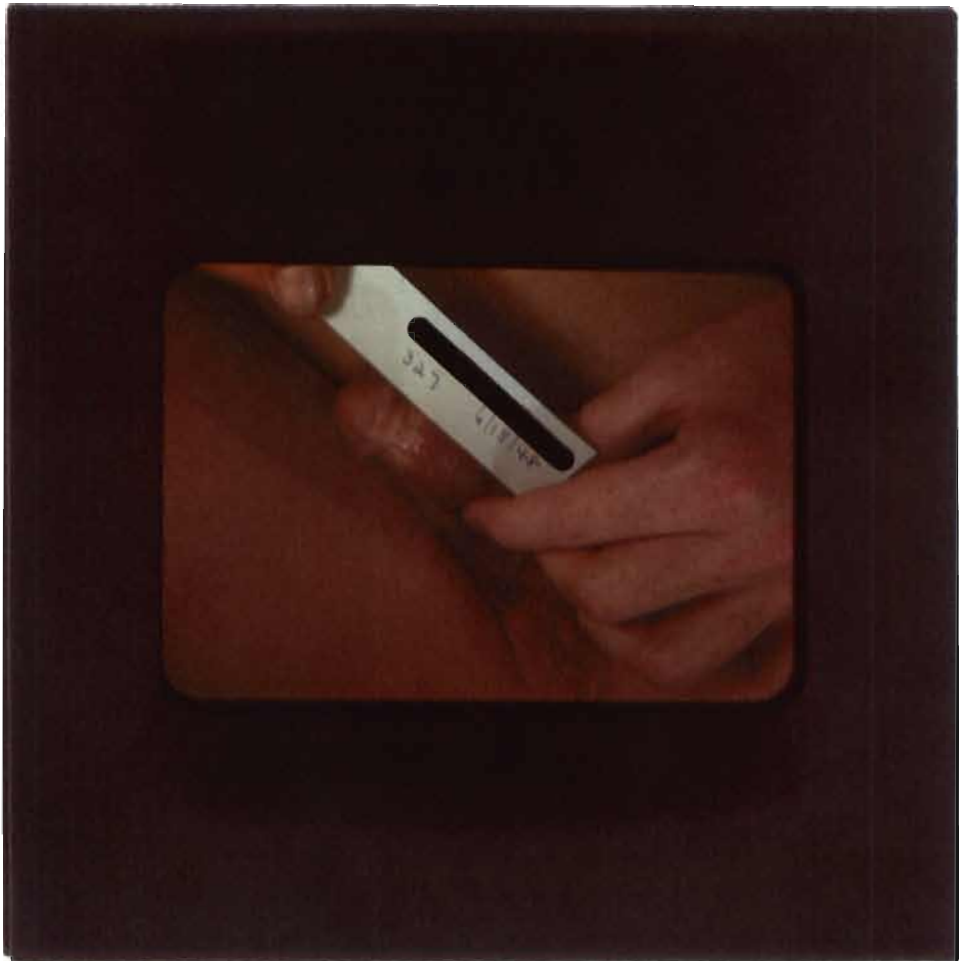6-24 46 2mm papule, unhealed

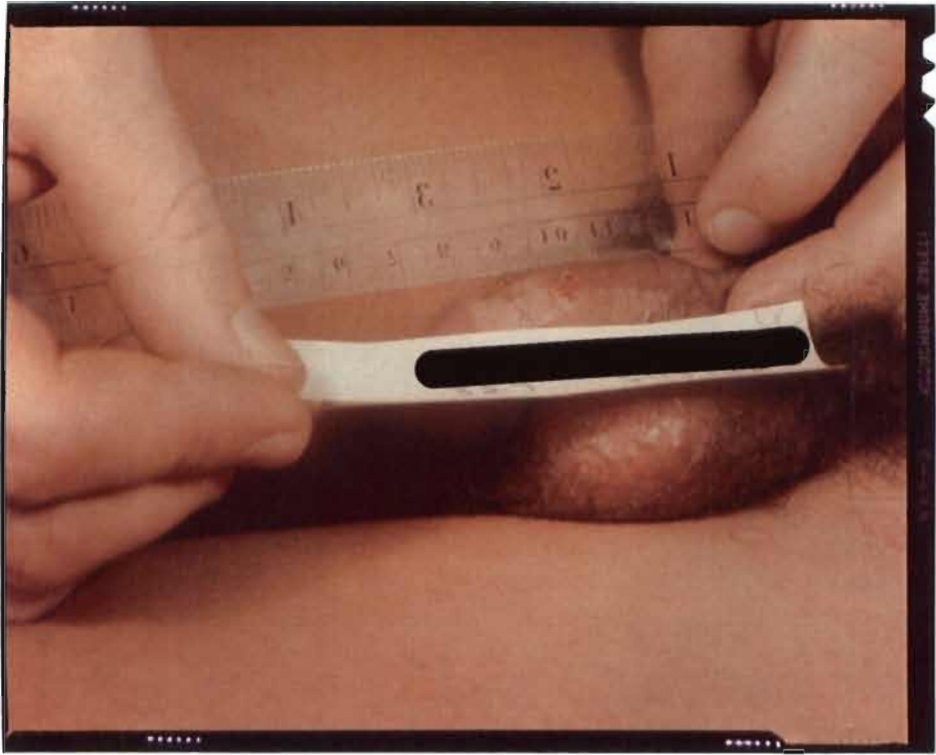
8-10 93 lesion healed but still
by body

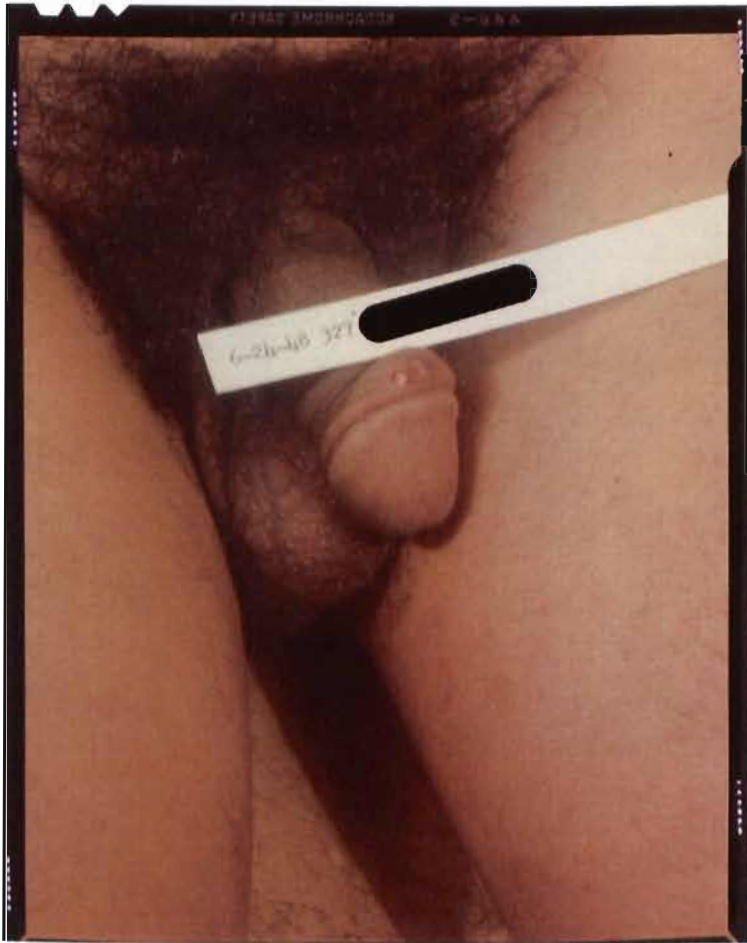327

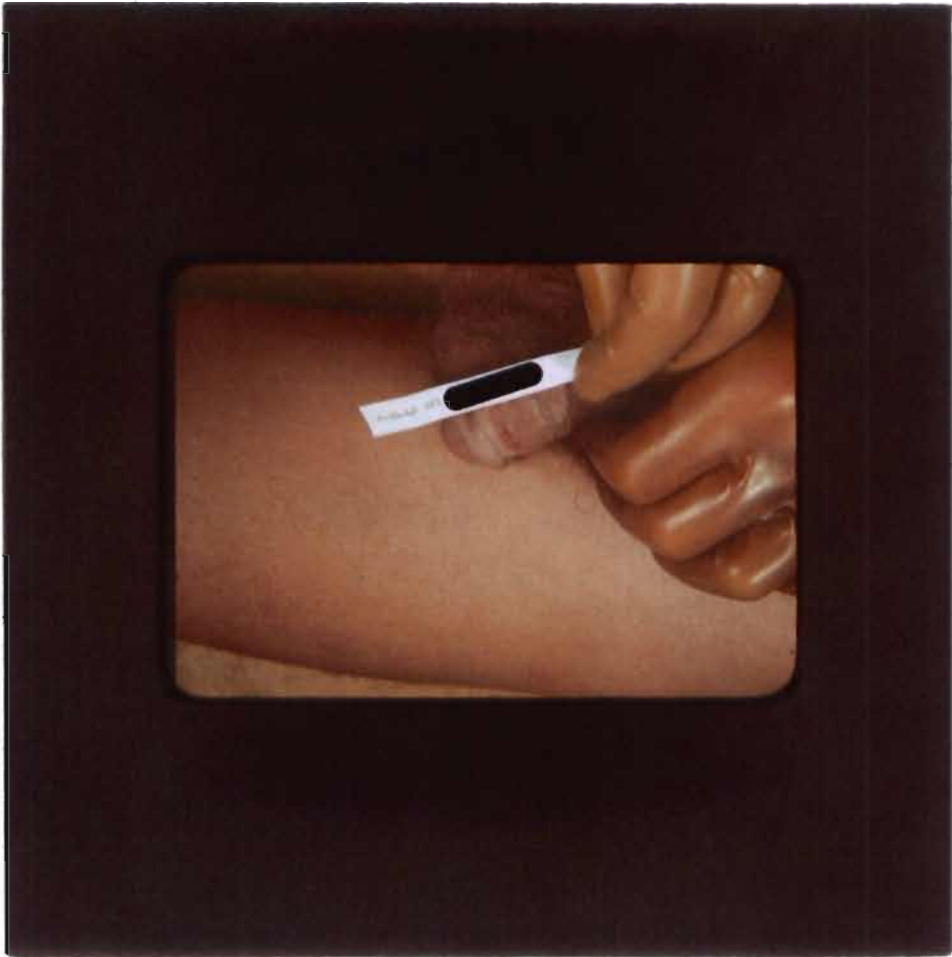[initials]











342

No. _____

Name _____

Order _____

Remarks _____

Retouched _____

Order Finished _____

Reorder _____

Reorder _____

5-9-45

Scar

6-15
37d

5 x 10 mm undercut, eroded
& crusted area

6-27 44d

15 x 10 mm raised plaque
c. atrophic, scaling
area, some crusting
& erosion.

perforated hole

7-14 NY

6led no change

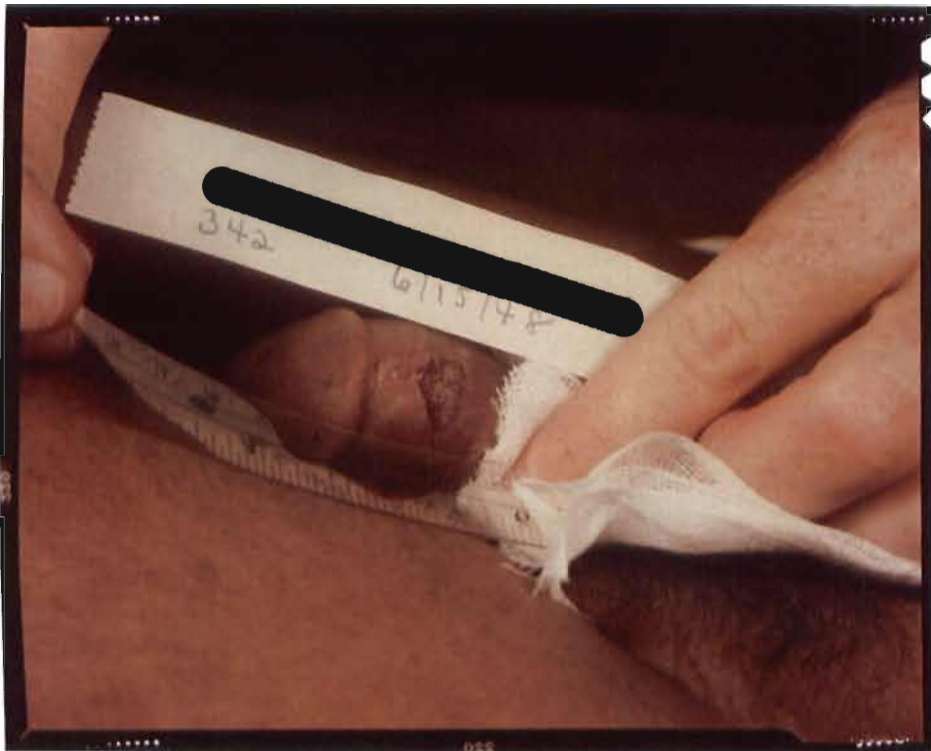17

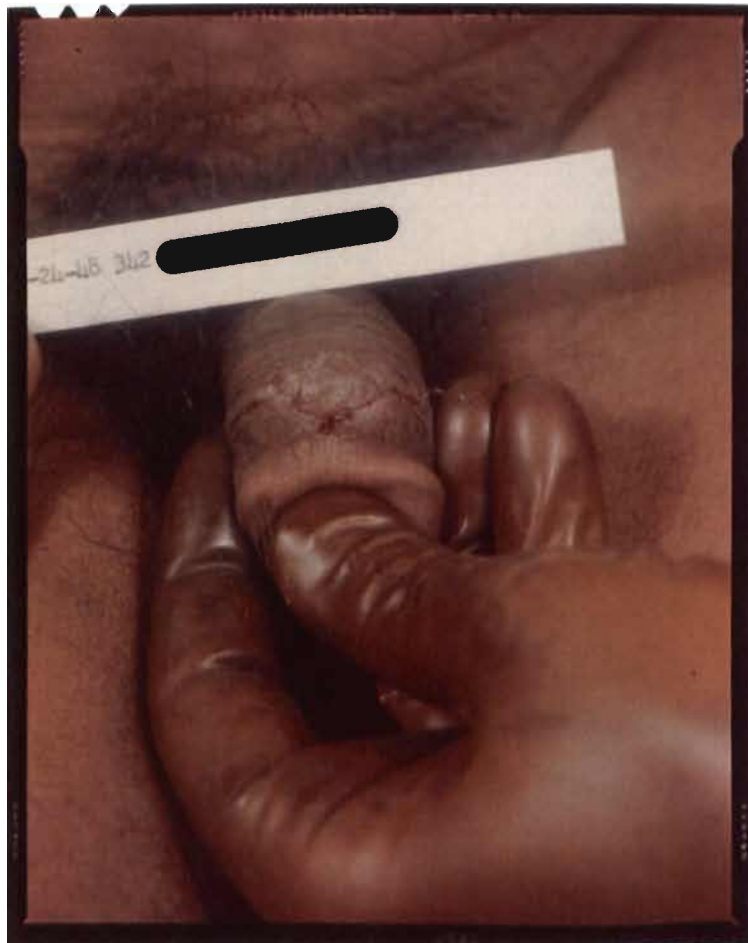342

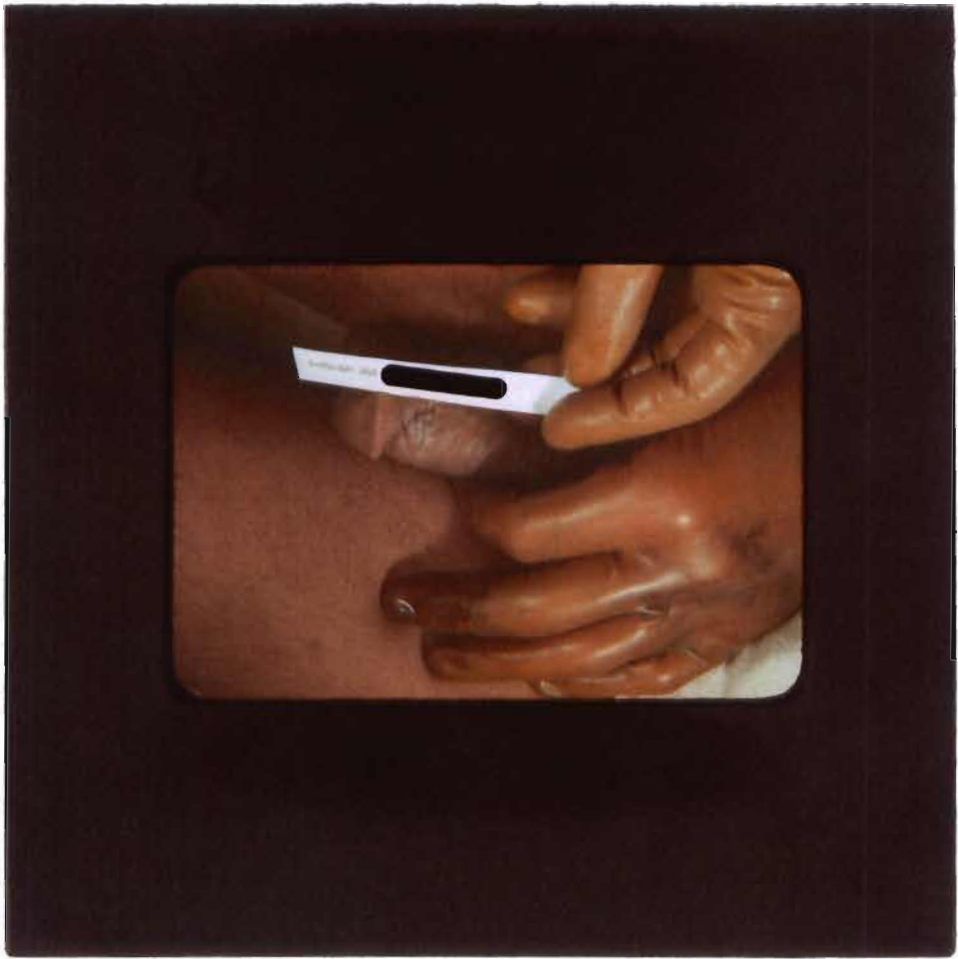











343

No. _____

Name _____

Order _____

Remarks _____

Retouched _____

Order Finished _____

Reorder _____

Reorder _____

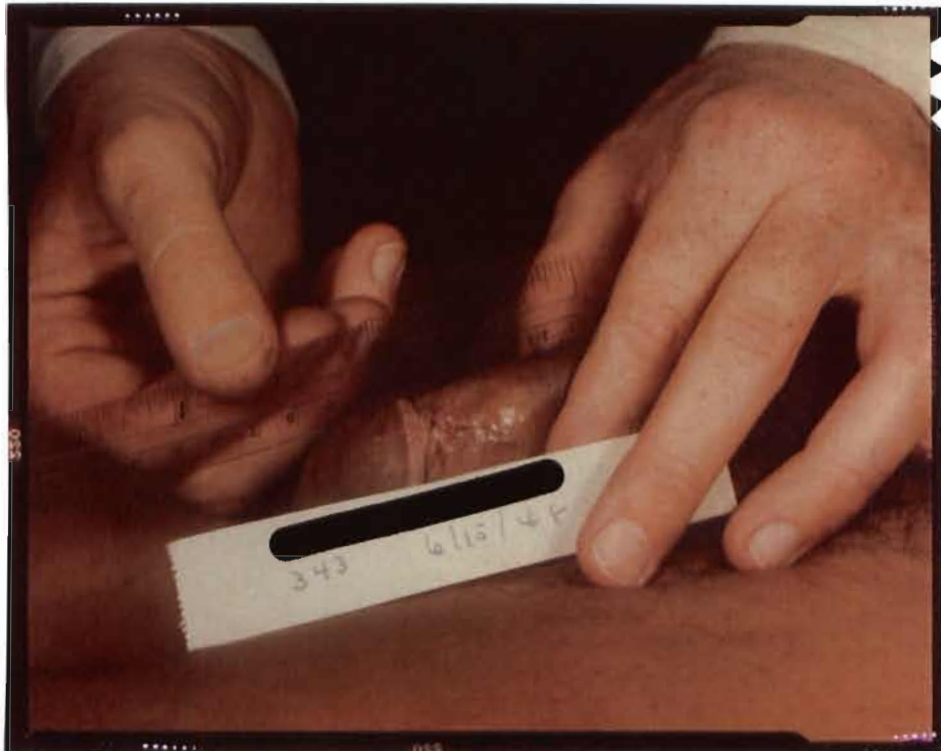
5-9-45 Scan

6-15 37d Indentation, reddening, erosion, scaling & crusty

4-24 46d 5x10mm indentation, eroded area; attrahing 1/4 of material by nodules

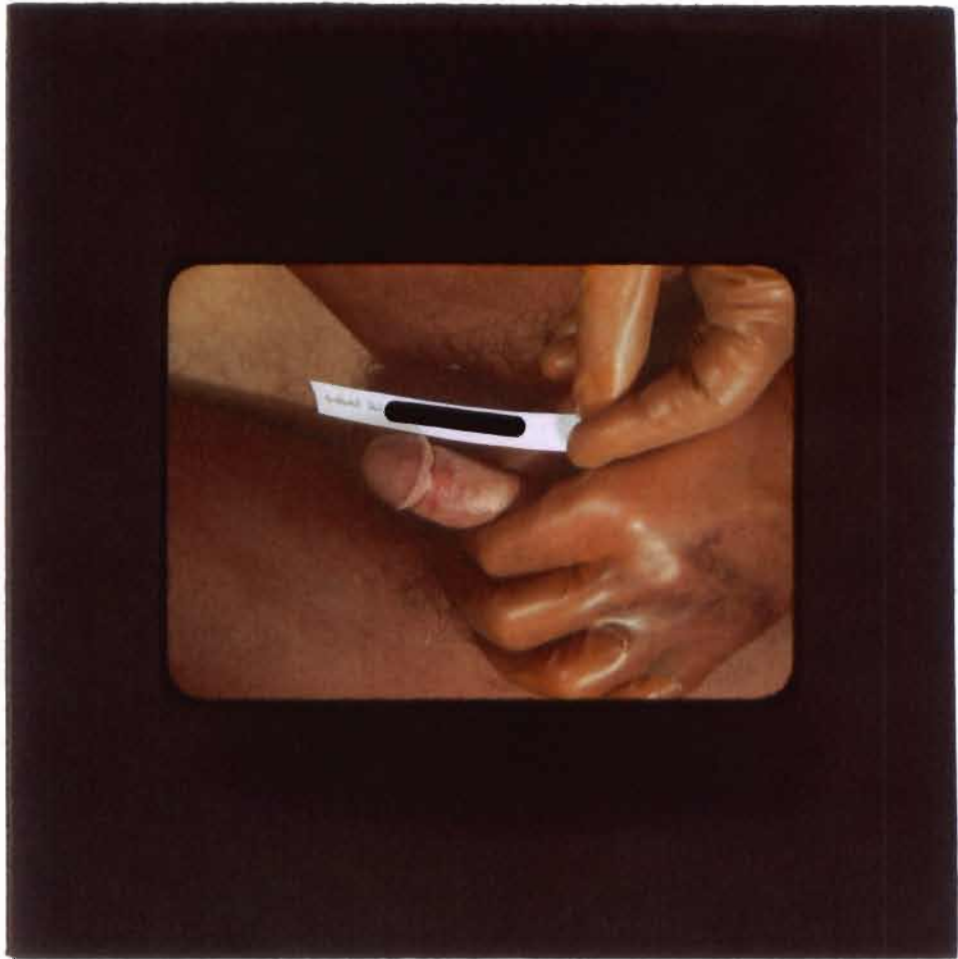343

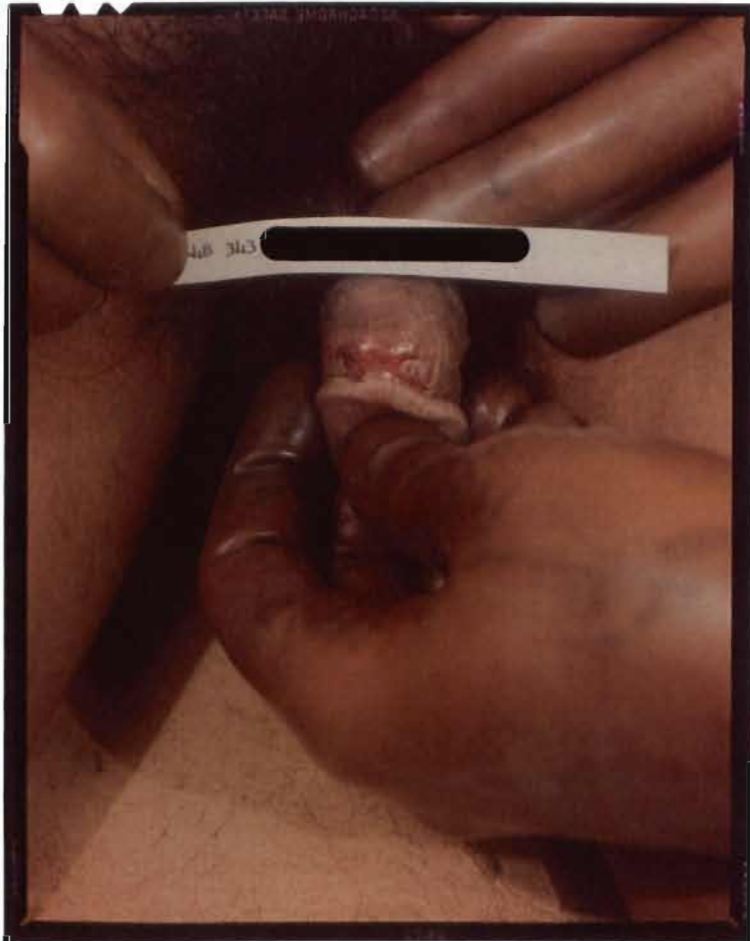7











Order

344

No. _____

Name _____

Order _____

Remarks _____

Retouched _____

Order Finished _____

Reorder _____

Reorder _____

5-9-45

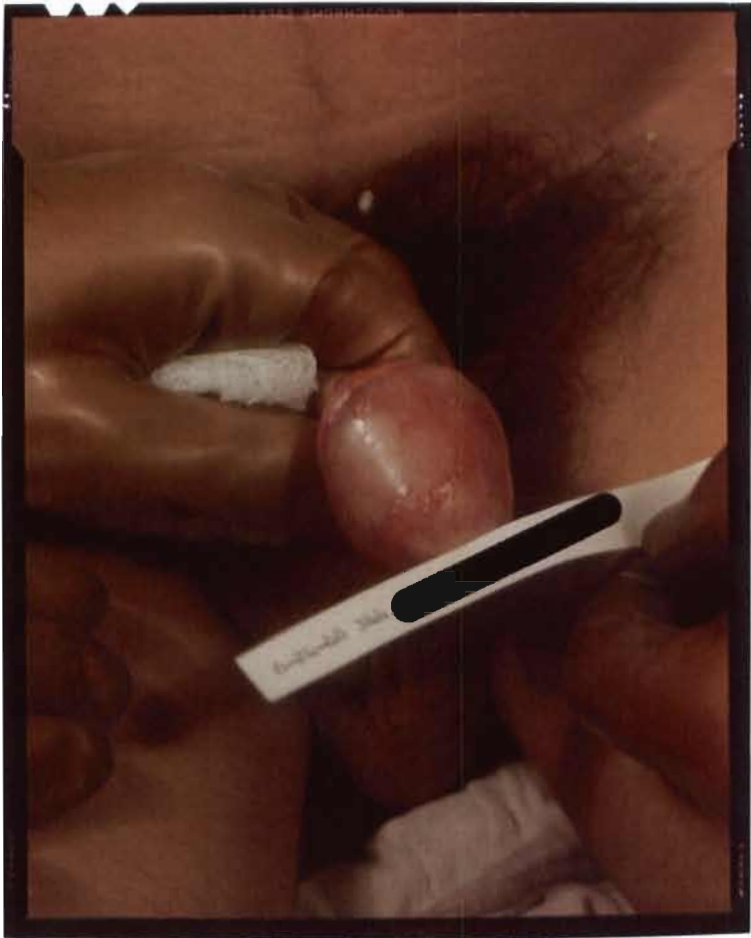5 car 1 h.

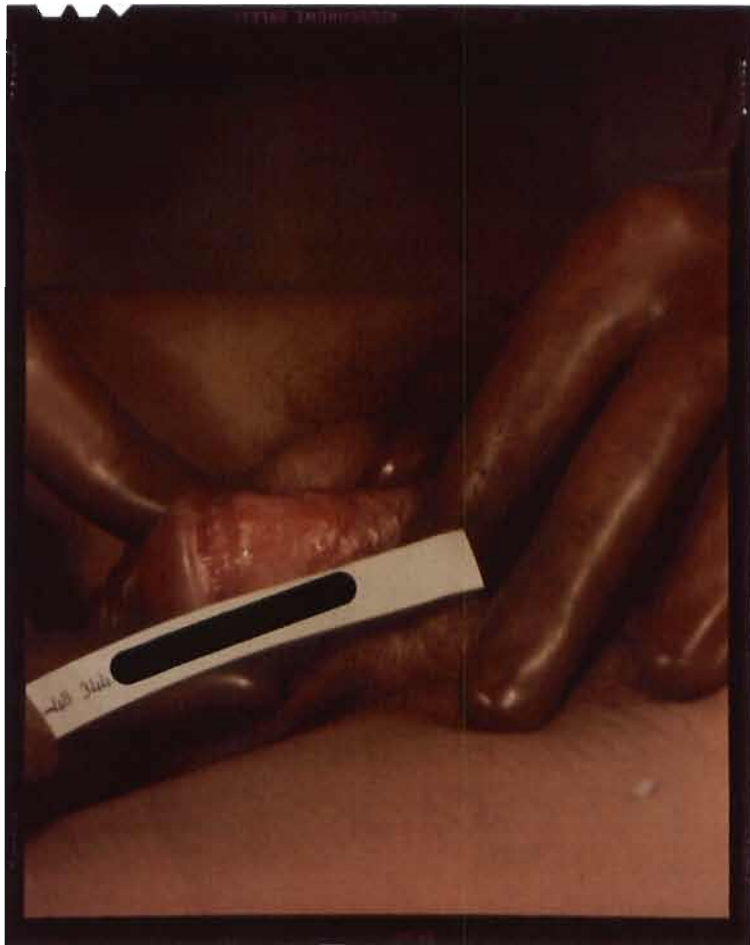
6-24-45

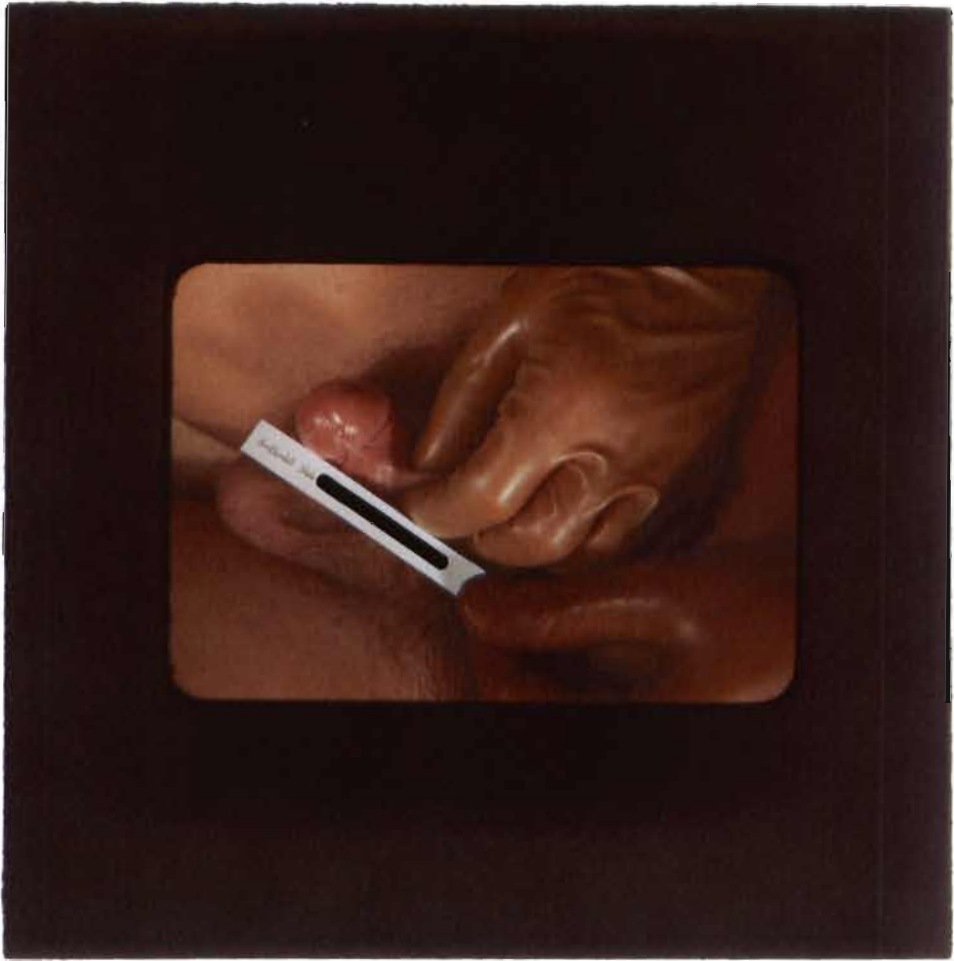46 d

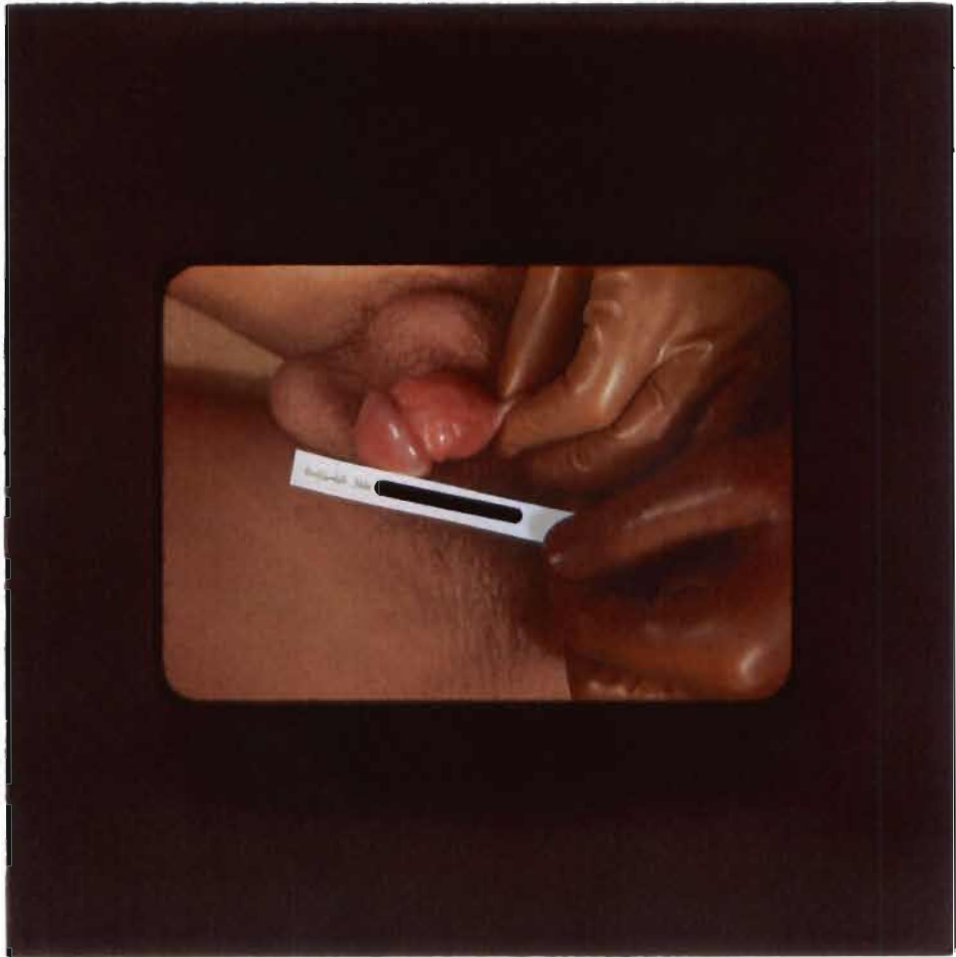Affix individual /
foreskin, oris +
glans + foreskin.
Ingenit adenopathy
DF +

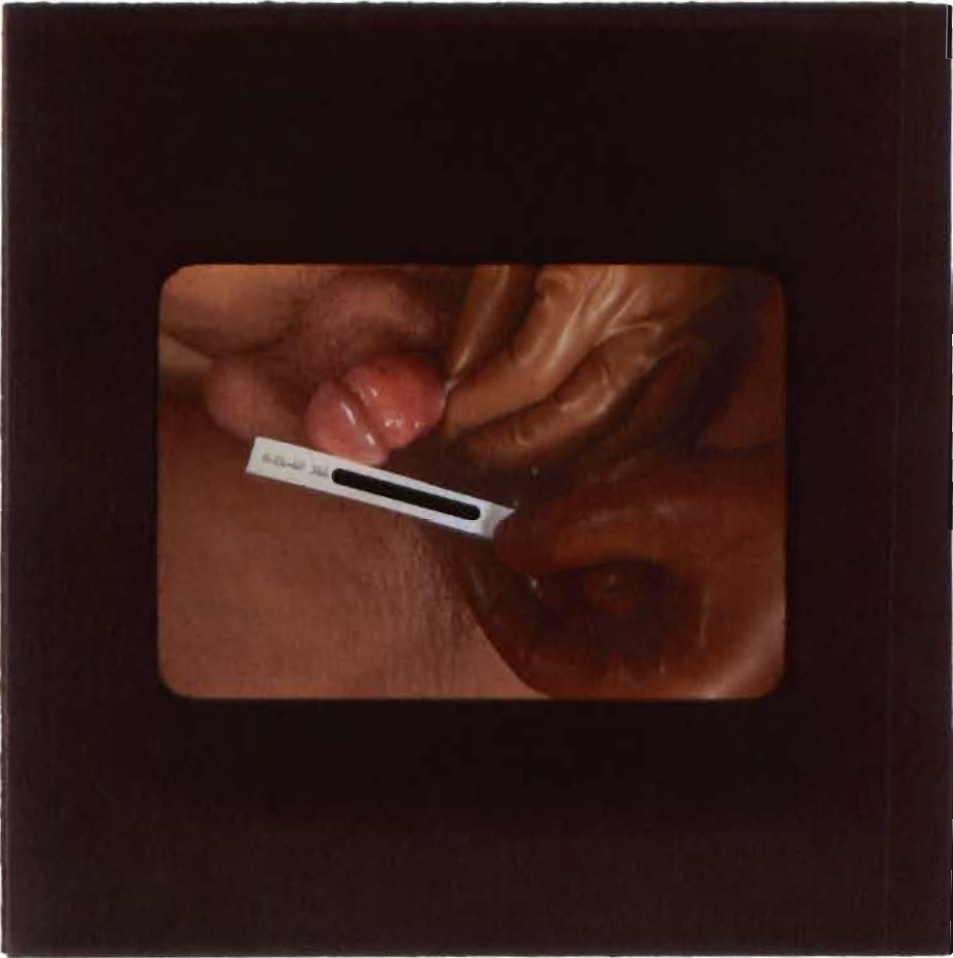5











No. _____

Name _____

Order _____

Remarks _____

Retouched _____

Order Finished _____

Reorder _____

Reorder _____

2-17-45

19

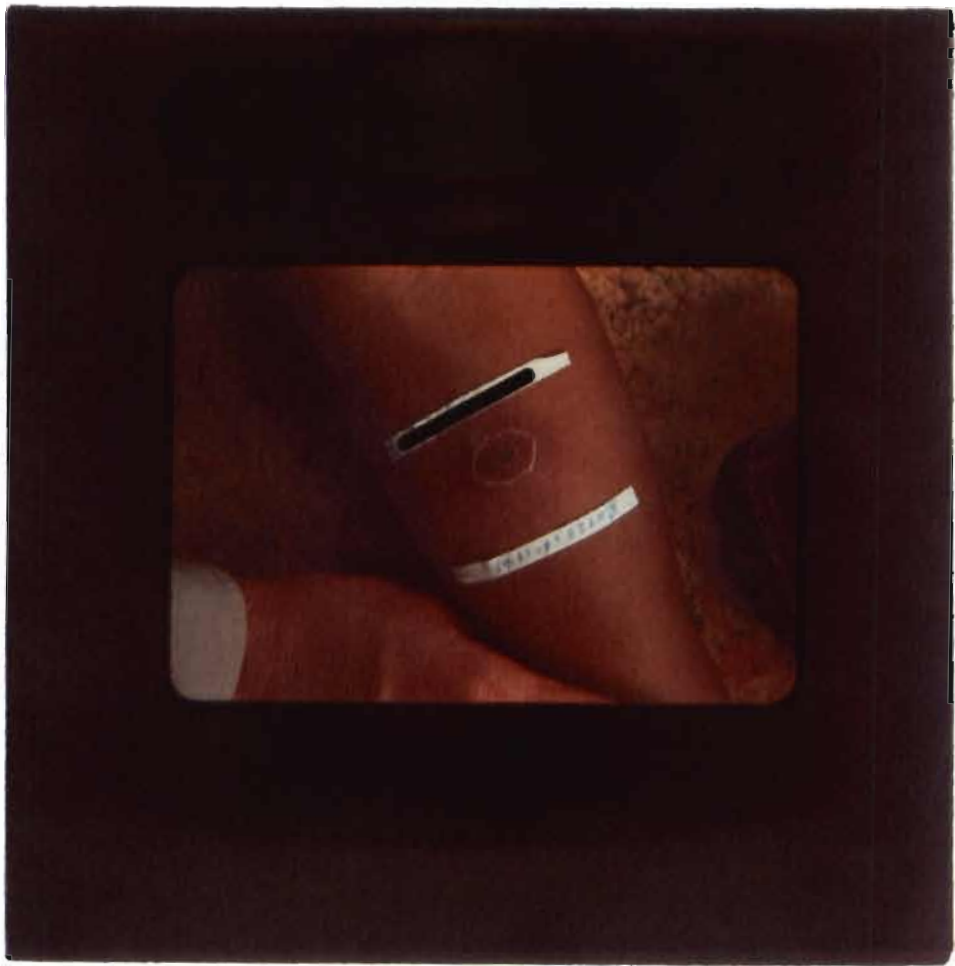- no 2

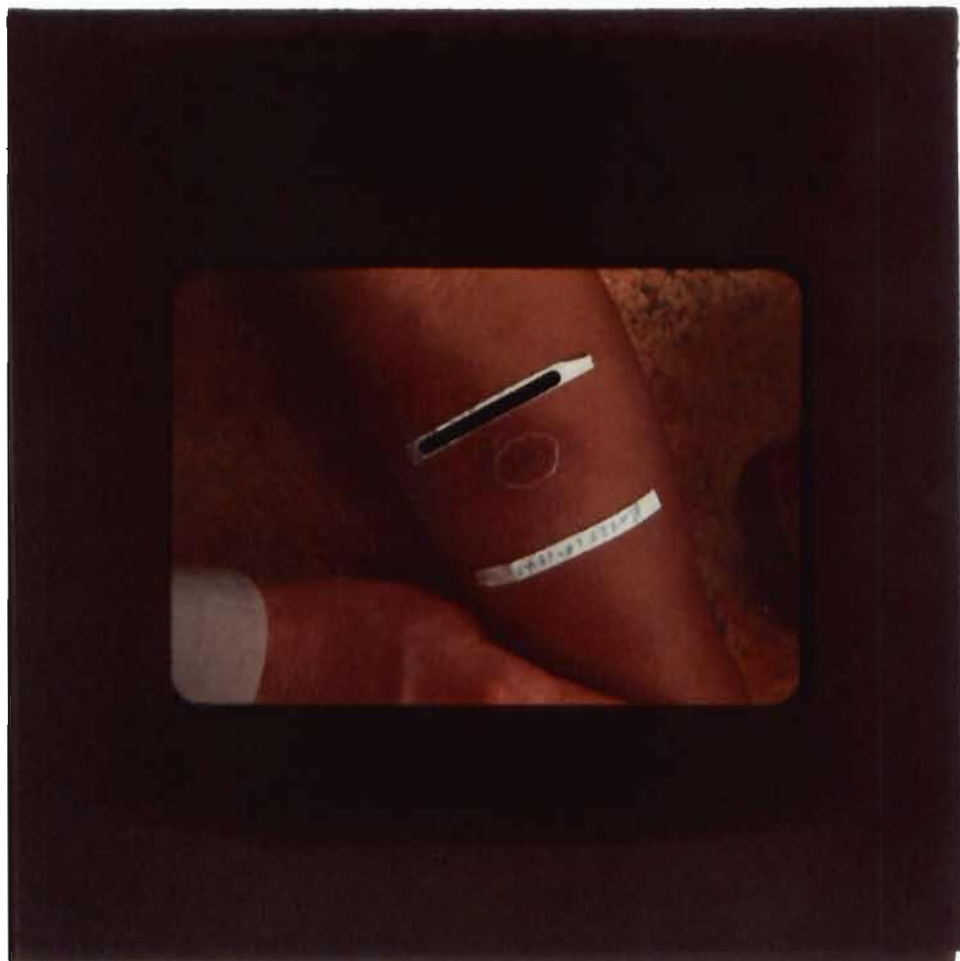3-10

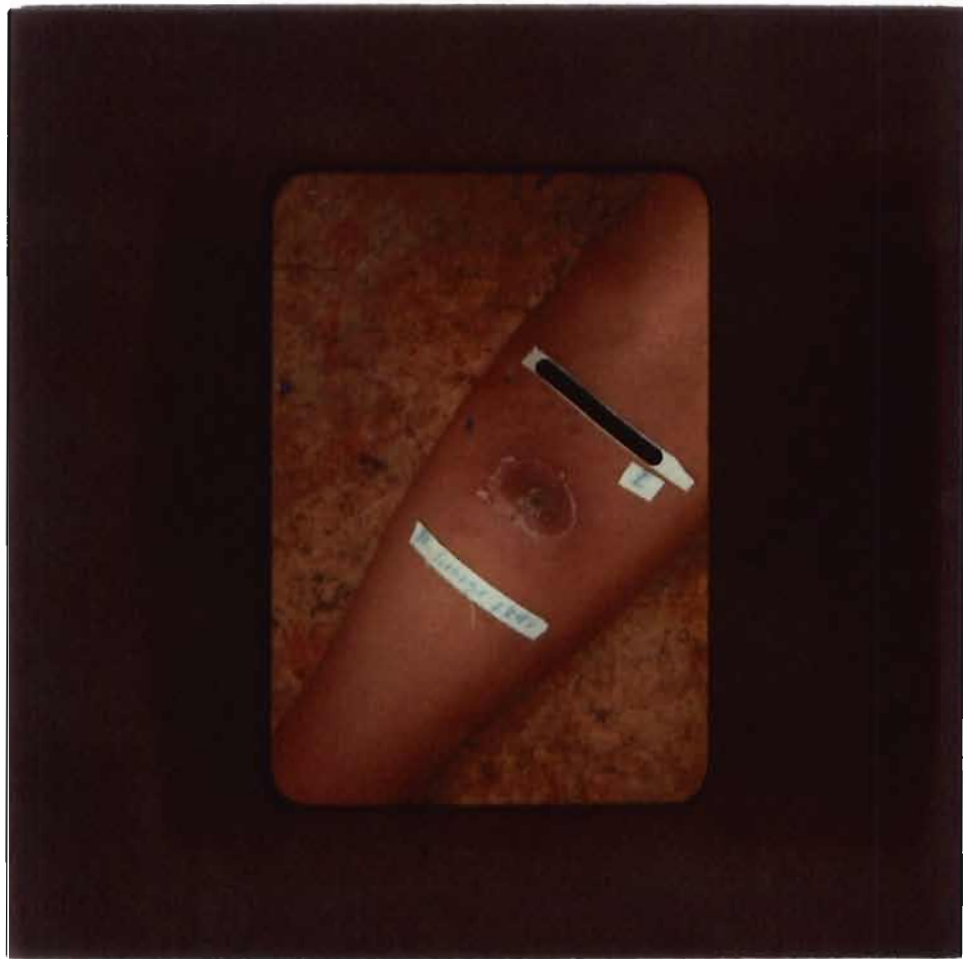3-14

3-27 - healing of 14 of 3-10

9









No. [REDACTED]

Name [REDACTED]

Order _____

Remarks _____

Retouched _____

Order Finished _____

Reorder _____

Reorder _____

5-14-47

1a

6-13

model i local IT lab

6-16

increasing calu

7-7

request

7-14

generalized IT

9







No. _____

Name _____

Order _____

Remarks _____

Retouched _____

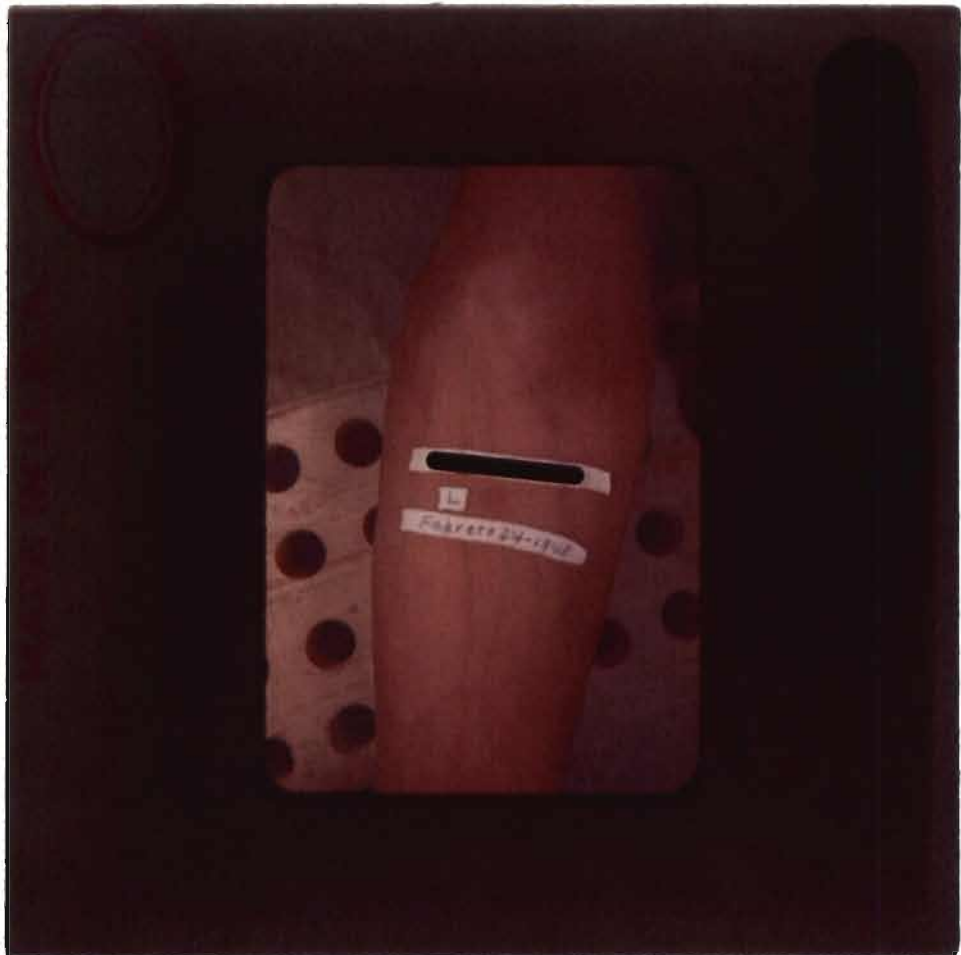Order Finished _____

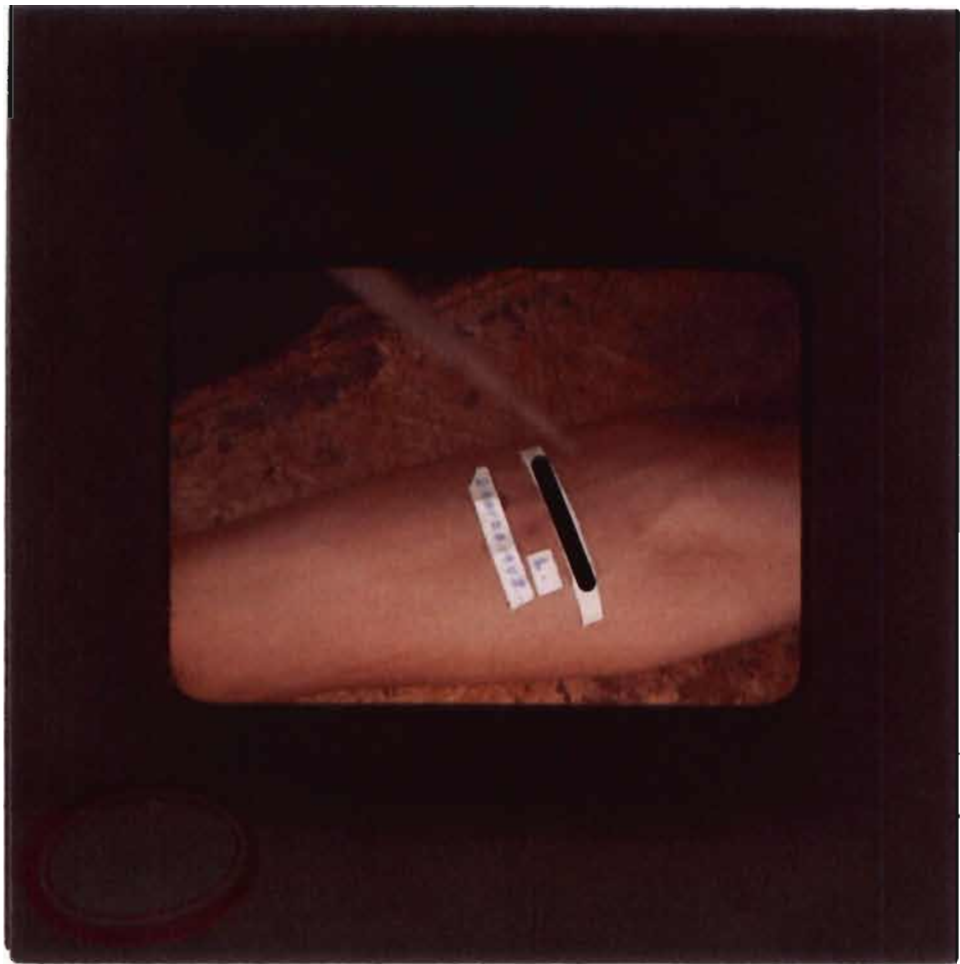Reorder _____

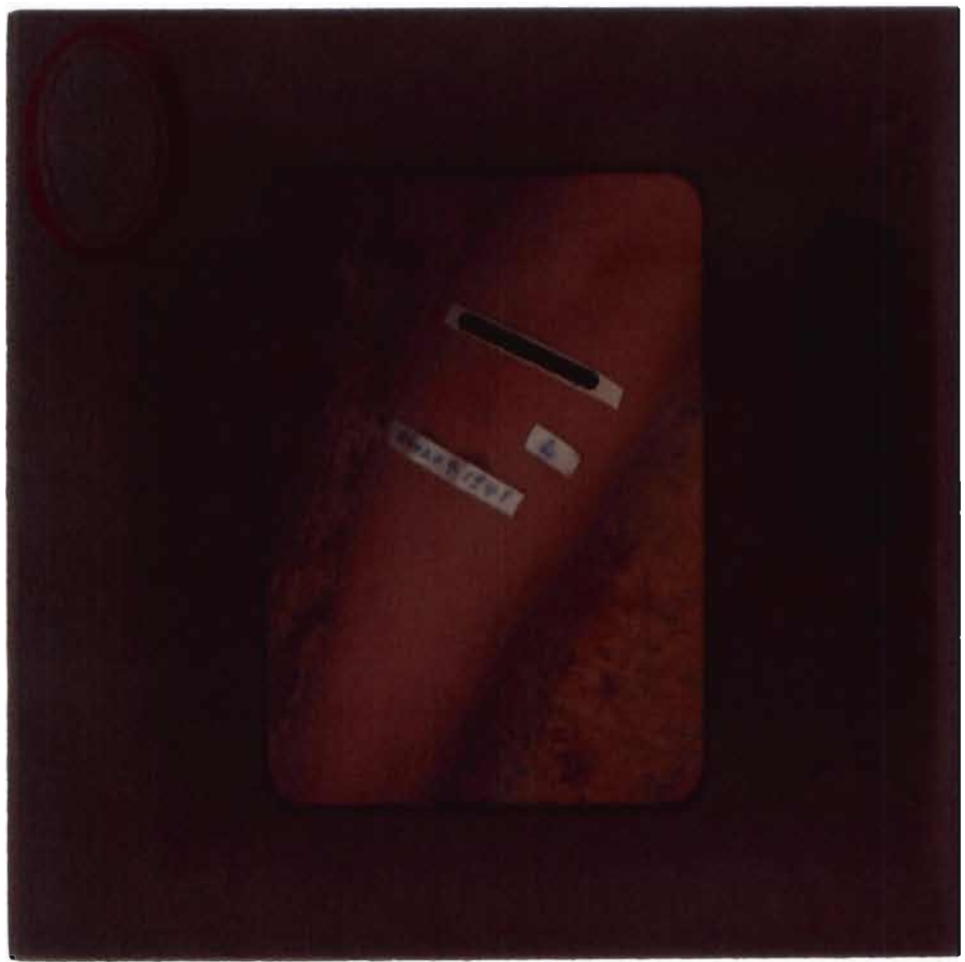Reorder _____

*very good
reorder by lhr*

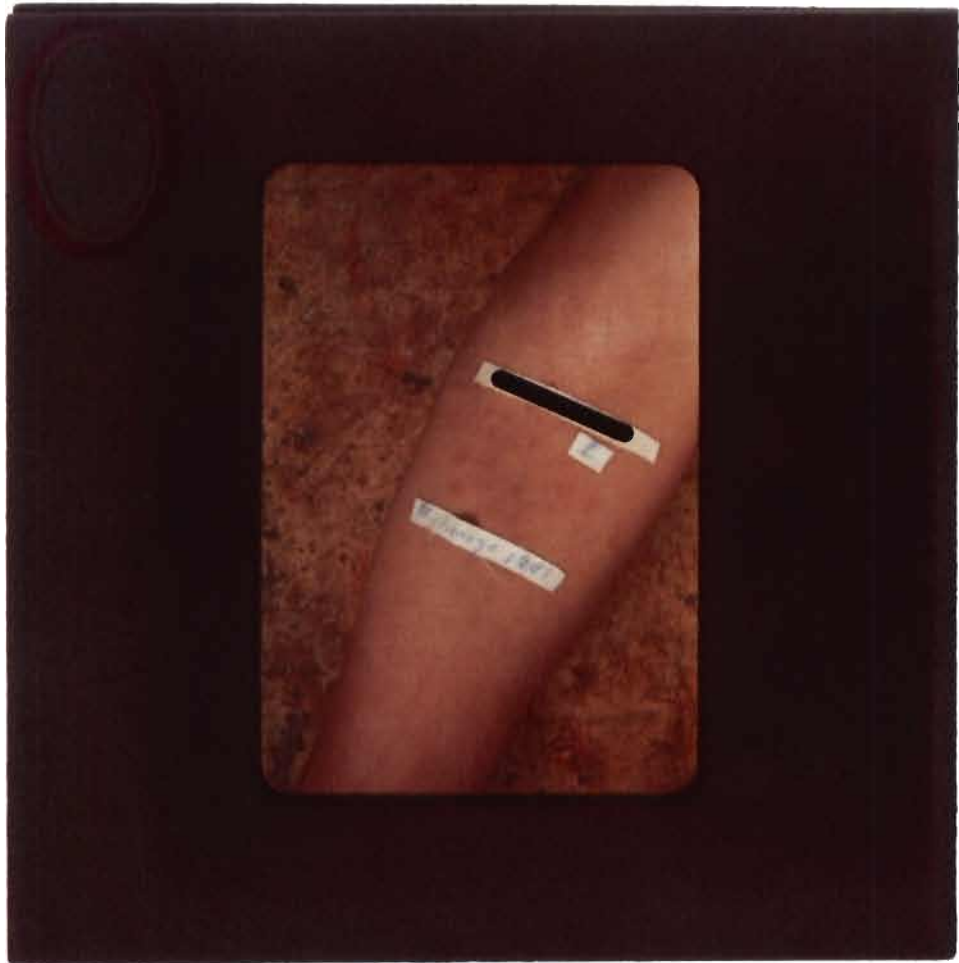9

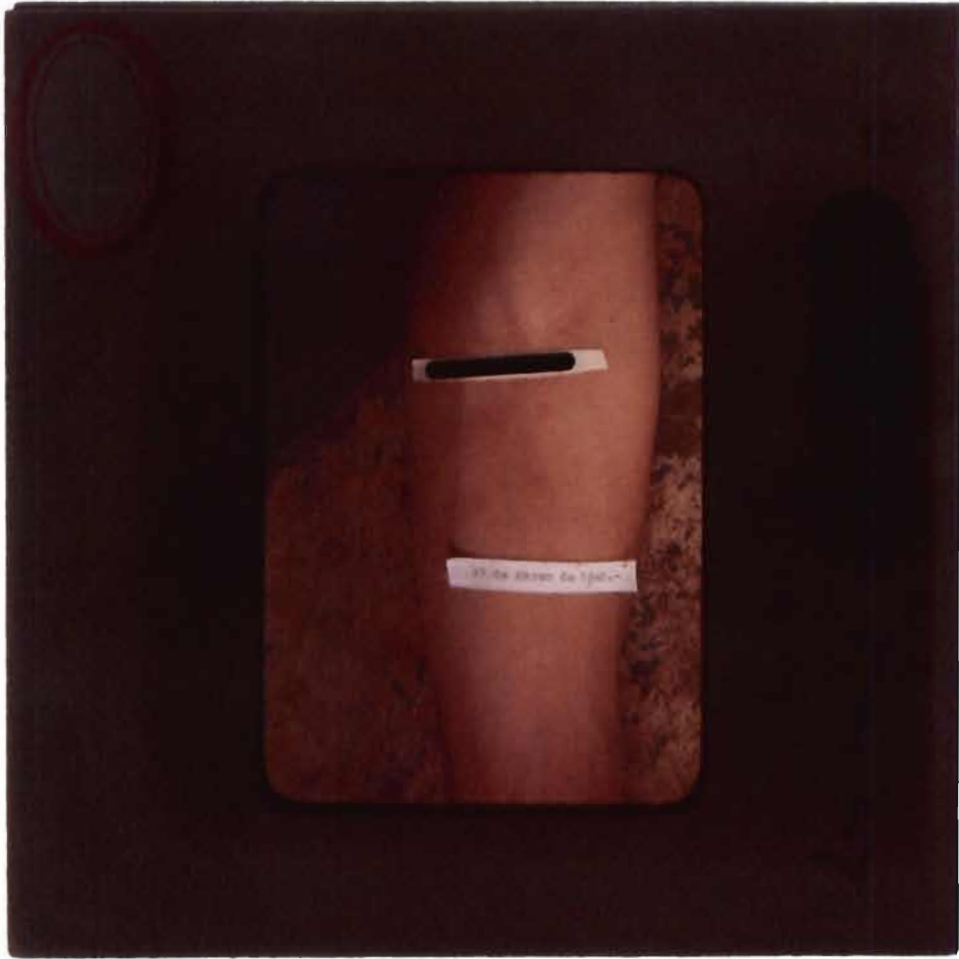













Per

No. 

Name 

Order _____

Remarks _____

Retouched _____

Order Finished _____

Reorder _____

Reorder _____

5-14-47 19 untreated latex

6-13 1 cm nodule

7-7 fading, scaly

7-13 generalized ii

H





7. VII. 42



per

No. [REDACTED]

Name _____

Order _____

Remarks _____

Retouched _____

Order Finished _____

Reorder _____

Reorder _____

2-14-45 19,

3-16

4





pa

No. [REDACTED]

Name _____

Order _____

Remarks _____

Retouched _____

Order Finished _____

Reorder _____

Reorder _____

6-13-47

F



13-647

pa

No. [REDACTED]

Name [REDACTED]

Order _____

Remarks _____

Retouched _____

Order Finished _____

Reorder _____


Reorder _____

8-7-47

7-12 7 mm paper
7-15 5 mm scaling, altophi. tubule

tt





Pen

No. _____



Name _____

Order _____

Remarks _____

Retouched _____

Order Finished _____

Reorder _____

Reorder _____

8-7-47

19

9-1

1x1cm mark

11



pen

No. [redacted]

Name [redacted]

Order Spolucos curi

Remarks immune undecidat

Retouched _____

Order Finished _____

Reorder _____

Reorder _____

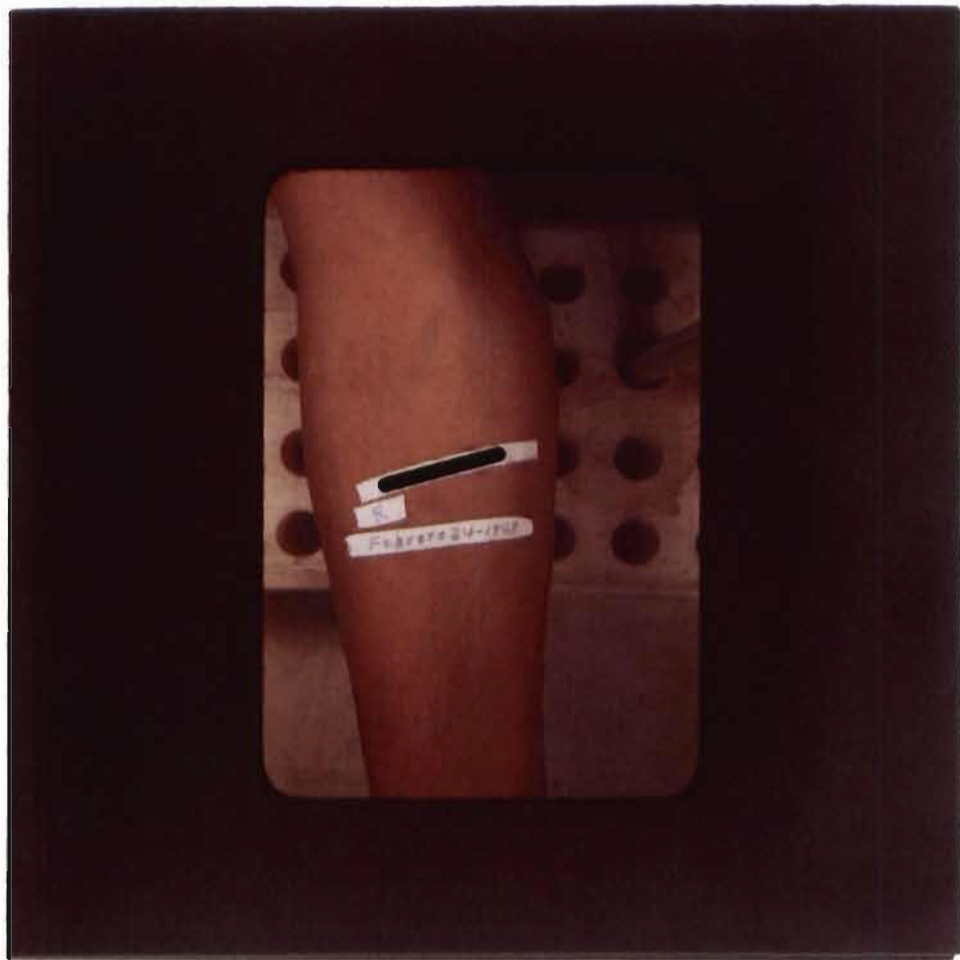2-14-48 19 undecidat h
undecidat H

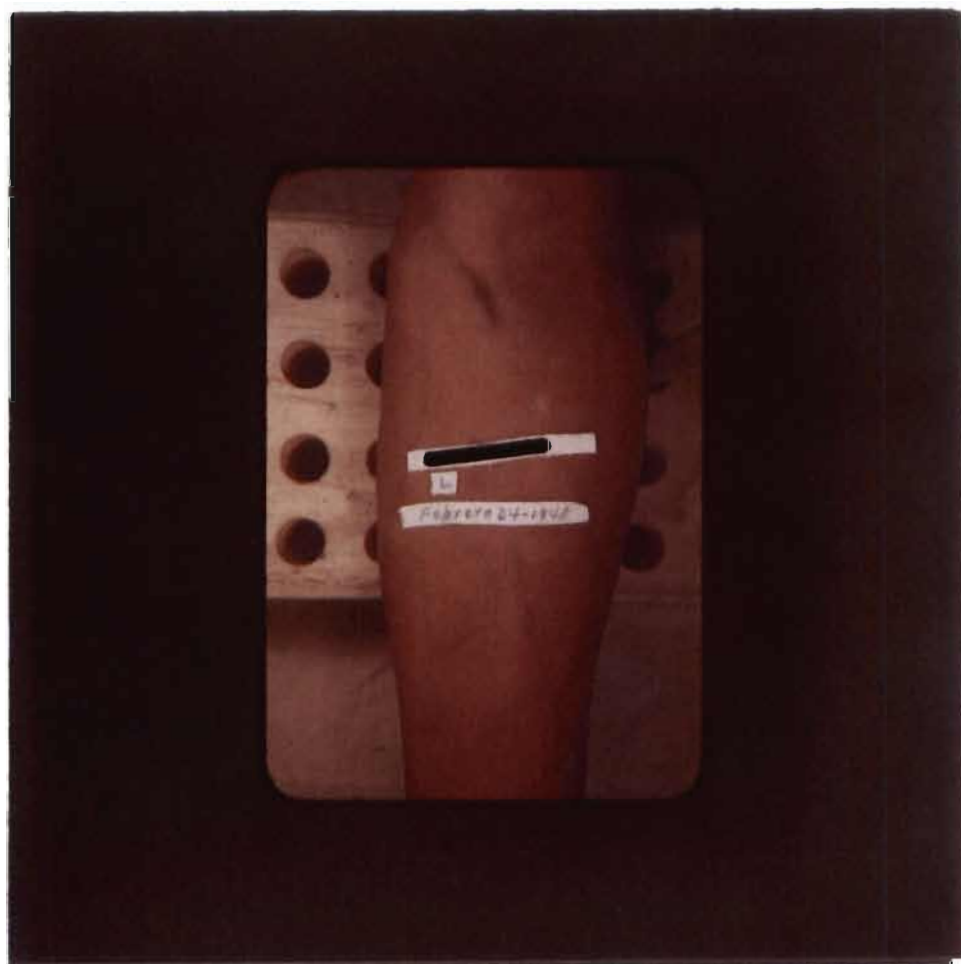2-24 h 5x5 undecidat, raised flap
H slight undecidat

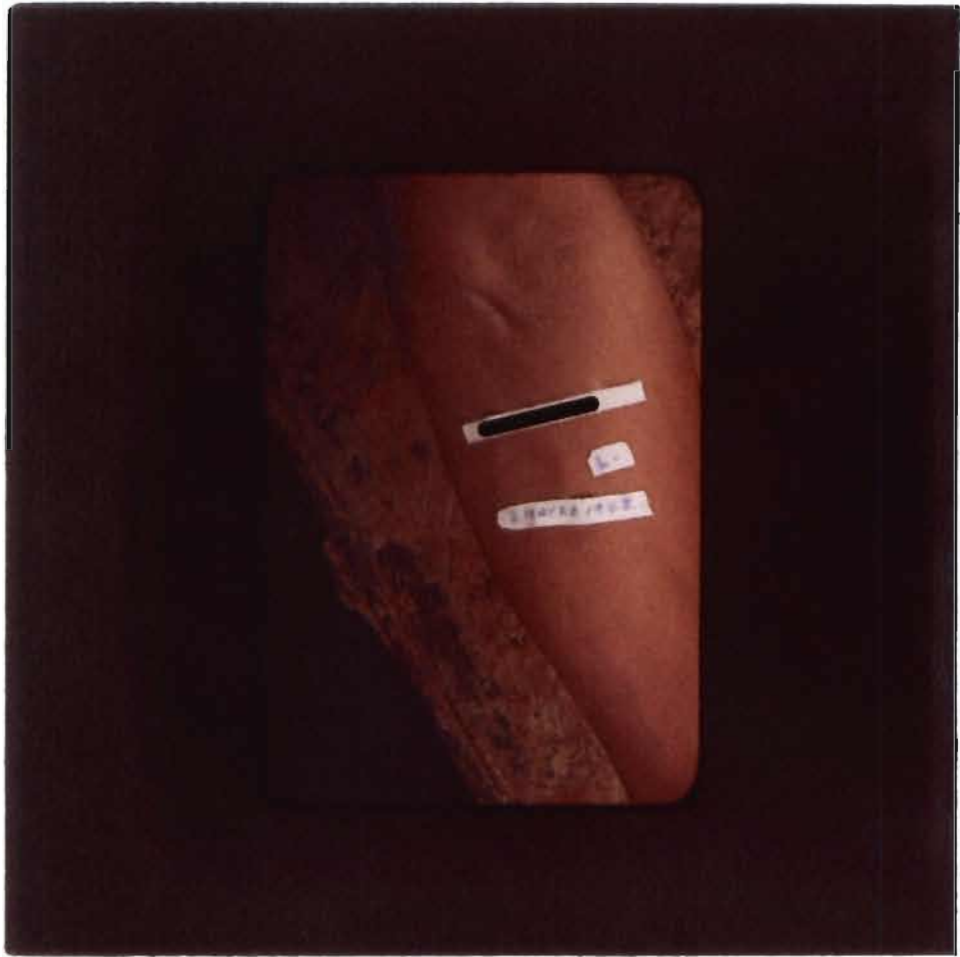3-2 h 4x4 slightly undecidat
H slight undecidat

3-1 h 4x4 undecidat

+













102

No. _____

Name _____

Order _____

Remarks _____

Retouched _____

Order Finished found _____

Reorder _____

Reorder _____

2-14-48 10,

2-24

7x7 in. thick, paper

3-2

2 in. rodent in skin

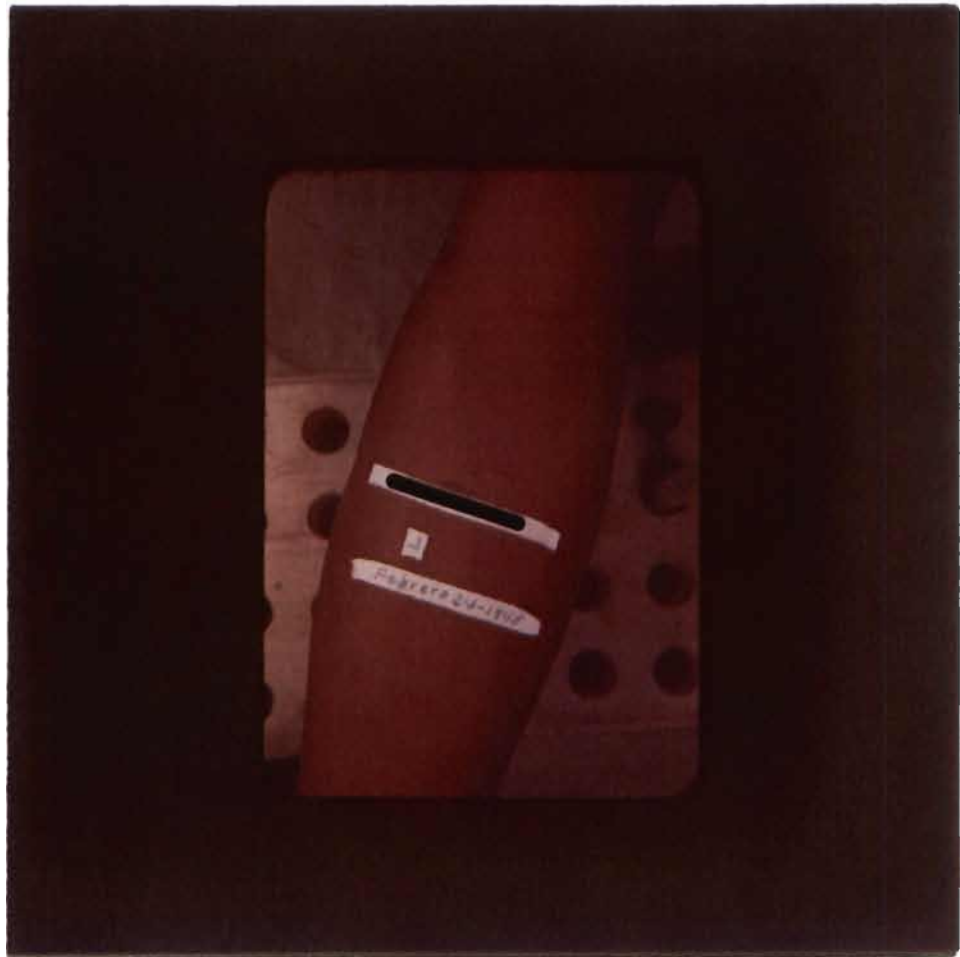
1-9

314 individual, signet, etc.

3-16

4x4 in. individual, signet, paper
spillows, rods enlarged

H



1a

No. _____
 Name _____
 Order _____
 Remarks _____
 Retouched _____
 Order Finished _____
 Reorder _____
 Reorder _____

5-14-47 19

5-23 7m diameter

6-13 3cm in diameter area, result,
 c making surface
 regional adumbently

6-16 depressed, making under
 M

TT